

OPIS PRZYPADKU
CASE REPORT**THE CASE OF FORMATION OF «KISSING» ULCERS OF DUODENAL BULB OF THE PATIENT WITH CHRONIC NONATROPHIC GASTRITIS ON THE BACKGROUND OF THE EATING OF A VEGETABLE SALAD AND PHYSICAL EXERTION****Anatoly A. Avramenko**

PETRO MOHYLA BLACK SEA NATIONAL UNIVERSITY, MYKOLAIV, UKRAINE

ABSTRACT

Introduction: In certain situations the constituents of food can serve as a catalysator for the formation of such a pathology as peptic ulcer. Not the last role in the formation of ulcerous defects under certain conditions play physical exertion, which is accompanied by sharp rhythmic contraction of the muscles of the anterior abdominal wall.

The aim: To analyze the case of formation of "kissing" ulcers of the duodenal bulb of the 25-year-old patient.

Materials and methods: The patient took comprehensive examination: step-by-step pH-metry, esophagogastroduodenoscopy, helicobacter infection test (HP) (helicobacter urease test and microscopic examination of stained smears), histological investigations of the gastric stump mucous, HELIC – test.

Case report: It was found that on the eve of the ulcer in the patient's diet during breakfast there was a salad of fresh white cabbage, fresh cucumbers, tomato and radishes and at lunch the patient was subjected to prolonged physical exercise. The level of gastric juice corresponded to the basal normacidity total; endoscopic diagnosis: «Kissing» ulcers duodenal bulb in an active stage. Chronic gastritis type B ». Testing for HP infection revealed a high concentration of the active form of bacteria, the HELIC -test showed a high concentration of ammonia in the stomach cavity.

Conclusions: An abrupt stimulation of secretion by cabbage juice and the presence of urea in vegetables, of which the salad was cooked, led to the formation of a large level of "residual ammonia" in the cavity of the stomach. Physical strain finally formed the mechanism of ulcer formation.

KEY WORDS: gastritis, *Helicobacter pylori*, "residual ammonia"

Wiad Lek 2019, 72, 5 cz. I, 946-949

INTRODUCTION

Food is an essential attribute of our daily life. However, in certain situations the constituents of food can serve as a catalysator for the formation of such a pathology as peptic ulcer. Not the last role in the formation of ulcerous defects under certain conditions play physical exertion, which is accompanied by sharp rhythmic contraction of the muscles of the anterior abdominal wall [1]. From this point of view, the interesting case of rapid formation of "kissing" ulcers of duodenal bulb after physical exertion, which were preceded by the meal in the form of fresh cabbage salad, fresh cucumbers, tomatoes, and radish.

THE AIM

To analyze the case of formation of "kissing" ulcers of the duodenal bulb.

MATERIALS AND METHODS

According to Order № 271 from 13.06.2005 of Ministry of HealthCare of Ukraine [2] a patient took comprehensive examination (№ 6420, 24.03.17), which included step-by-step pH-metry based on V.N. Chernobroviy methods,

esophagogastroduodenoscopy (EGDS) based on general techniques, helicobacter infection test (HP) (helicobacter urease test and microscopic examination of stained smears) and histological investigations of the gastric stump mucous, biopsy material was taken from 4 topographical zones of the stomach (medial third part of antrum and body of the stomach through large and small curvature) [3, 4, 5]. Also, the patient was additionally given a respiratory test (HELIC- test) to determine the level of HP infection according to the latest modification of the method [6].

The study was conducted in accordance with the basic bioethical provisions of the Helsinki Declaration of the World Medical Association on the ethical principles of scientific 549 medical research involving human (1964-2008) and the order of the Ministry of Health of Ukraine No. 690 dated September 23, 2009, which was confirmed by the findings of the meeting of the Ethical Commission of Petro Mohyla Black Sea National University, Nikolaev No. 2 dated February 12, 2019.

CASE REPORT

Patient (man) B., 25 years old, asked 13.03.17 y. for the examination and treatment of a doctor-gastroenterologist

Table I. Test results of gastric mucosa on HP infection for topographical zones

Antrum				Fundus of stomach			
Large curvature		Small curvature		Large curvature		Small curvature	
Microscopic analysis	Urease test	Microscopic analysis	Urease test	Microscopic analysis	Urease test	Microscopic analysis	Urease test
(+++) Active form, mitosis	15 min	(+++) Active form, mitosis	15 min	(+) Active form, mitosis; (+++) Cocci form	1 h 20 min	(+) Active form, mitosis; (+++) Cocci form	2 h

of the clinical department of basic research laboratory on chronic *Helicobacter Pylori* infection of the Petro Mohyla Black Sea National University about periodic dull and acute pain in epigastria, feeling of heaviness after eating, heart-burn after taking sour food. In history, it was found that the first manifestations (epigastric pain) appeared when he was 21 years old against the background of stress. In further aggravations became regular every year and were seasonal (spring/autumn). The current aggravation have appeared in a day after taking the meal for breakfast (fresh cabbage salad, fresh cucumbers, tomatoes, and radish), which was followed by prolonged physical exertion as lifting weights during the lunch time.

The following results were obtained when carrying out investigations:

pH - metry (by V.N. Chernobrovyi method)

Surname. First Name. Patronimic.: B., 25 years

Height: 180 cm; introduced 25 cm

1. 2.79 1.68 11. 1.99 1.70

2. 2.80 1.63 12. 1.99 1.73

3. 2.81 1.64 13. 1.93 1.72

4. 2.84 1.78 14. 1.95 1.83

5. 2.85 1.70 15. 1.95 1.80

6. 2.59 1.71 16. 1.96 1.84

7. 2.49 1.70 17. 1.80 1.85

8. 2.40 1.68 18. 1.81 1.80

9. 2.41 1.69 19. 1.91 1.83

10. 2.40 1.69 20. 1.92 1.82

5. - -

4. - -

3. 10 20

2. 10 -

1. - -

0. - -

Total: 20 20

Diagnosis: Basal normacidity total. 24.09.16 y.

The following diagnosis was made when carrying out esophagogastroduodenoscopy: «Kissing» ulcers duodenal bulb in an active stage. Chronic gastritis type B ». When

testing the gastric mucosa on HP infection for topographical zones were obtained the following results (table I).

While conducting examination of histological research the results have been obtained which confirms the presence of chronic active gastritis in all parts of the patient's stomach. When conducting the HELIK - test no. 7, 25.03.2017 year, the following results were obtained:

a) basic level: 0.5 mm;

b) load level: 6 mm;

c) growth rate: 5.5 mm;

d) conclusion about HP infection-infection (norm-growth up to 3 mm): positive (before treatment).

DISCUSSION

This case can be explained from the position of the new theory of ulcer forming - theory "caustic alkali spit" [1]. Juice of cabbage that exudes while cutting this vegetable, has a distinct stimulating effect on the secretion of the stomach, which leads to increased levels of acidity in the stomach, so it is contradicted for people with gastritis with hyperacidity [7]. Nitrogenous fertilizers may exist in fresh cucumbers, tomatoes and radish, in particular, urea, used to accelerate growth and maturation of vegetables [8, 9].

Pylori infection, singling out the enzyme urea, converts urea into ammonia, which while combining with water forms ammonium hydroxide - caustic alkali, necessary bacteria to neutralization of excess hydrochloric acid around it [1, 10, 11, 12, 13, 14, 15]. However, some ammonia ("residual" ammonia (RA) does not participate in the process of neutralization of the hydrochloric acid, and fills the stomach. With physical rhythmic stress, according to a new theory, effect of "bellows sound" occurs, when RA concentrates in a tight place - in the pillory channel and bulb of the duodenum, where the humidity is 98%. This leads to local formation on duodenal mucosa ammonium hydroxide at high concentration, causing damages to the mucous membrane, known as peptic ulcer [1]. Graphically, this process can be represented as follows (Figure 1).

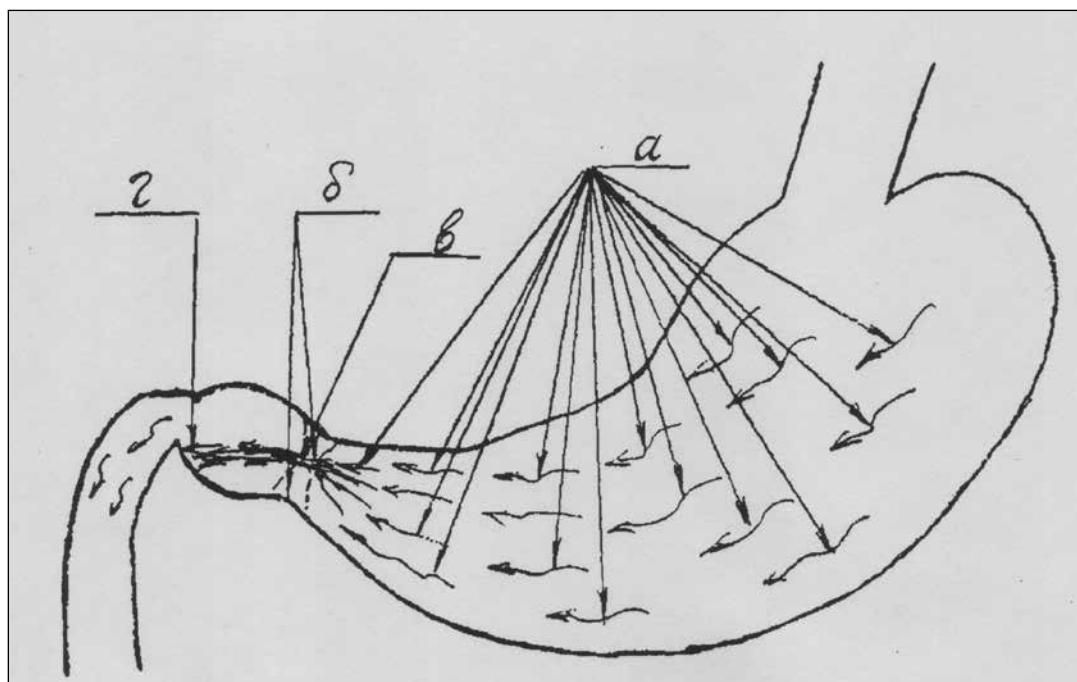


Figure 1. The mechanism of formation of ulcerative lesions of the duodenal bulb in patients with chronic helicobacteriosis:
a) flow direction “residual” ammonia in the gastric cavity;
b) the pyloric sphincter in half-bent state;
b) the place of the maximum concentration of “residual” ammonia (pyloric canal) in the form of sustainable dense flow;
r) the place of ulcerative lesions of the duodenal bulb tissues (any bulb department duodenal ulcer).

CONCLUSIONS

1. An abrupt stimulation of secretion by cabbage juice and the presence of urea in vegetables, of which the salad was cooked, led to the formation of a large level of “residual ammonia” in the cavity of the stomach.
2. Physical strain finally formed the mechanism of ulcer formation.

REFERENCES

1. Avramenko AA, Gozhenko AI, Goydyk VS, eds. *Yazvonnaya bolezn (ocherki klinicheskoy patofiziologii)* [Peptic ulcer disease (essays on clinical pathophysiology)]. Odessa : OOO «RA «ART-V», 2008. 304 s. (Ru).
2. Nakaz MOZ Ukraïni vid 13.06.2005 № 271 «Pro zatverdzhennja protokoliv nadannja medichnoï dopomogi za special'nistju «Gastroenterologija» [On Approval of Protocols for the Provision of Medical Aid in the Specialty «Gastroenterology»]. (UA).
3. Avramenko AA. Dostovernost stul-testa pri testirovanii bolnykh khronicheskim khelikobakteriozom pri nalichii aktivnykh i neaktivnykh form khelikobakternoj infektsii na slizistoy obolochke zheludka [Reliability of stool test when testing patients with chronic *Helicobacter pylori* in the presence of active and inactive forms of *Helicobacter pylori* infection on the gastric mucosa]. *Suchasna gastroenterologija*. 2014; 3 (77): 22–6. (Ru).
4. Patent 93273 Ukraine, MPK G01N 33/48 (2006.01) Sposib testuvannya gelikobakternoj infektsii u khvorikh na khronichnij gelikobakterioz [Method of testing helicobacteric infection in patients with chronic helicobacteriosis] / AO Avramenko. № u201403956; zayavl. 14.04.2014; opubl. 25.09.2014; 18:3. (UA).
5. Kímakovich VY, Nikishaev VI, eds. *Yendoskopiya travnogo kanalu. Norma, patologiya, suchasni klasifikatsiyi* [Endoscopy of the digestive canal. Norm, pathology, modern classifications]. Lviv: Vidavnistvo Meditsina Svitu, 2008. 208 s., il. 4. (UA).
6. Patent № 128945 Ukraine, MPK G01N 33/497(2006.01), A61B 5/091(2006.01) Sposib testuvannya gelikobakternoj infektsiyi u hvorih na khronichnij gelikobakterioz za dopomogoyu HELIK-testu [A method for testing helicobacter infection in patients with chronic helicobacteriosis using the HELIC -test] / AO Avramenko, OA Avramenko. – u 2018 05050; Zayavl. 07.05.2018; Opubl. 10.10.2018; 19:3.
7. Sok belokochannoj kapusty [White Cabbage Juice] [Elektronnyj resurs] // Rezhim dostupa: <https://nourriture.ru/stati-po-produktam/1410761/>. <https://nourriture.ru/stati-po-produktam/1410761/> (Ru)
8. Malahova LP, eds. *Produkty bez tajn! Zashiti svoj stol ot ulovok pishevoj industrii* [Products without secrets! Protect your table from the tricks of the food industry]. M. : Eksmo, 2012. 271 s.:il. (Ru).
9. Primenenie i harakteristika mocheviny kak udobreniya [Application and characterization of urea as a fertilizer] [Elektronnyj resurs] // Rezhim dostupa: <http://goodgrunt.ru/nazvaniya/mochevina-udobrenie.html> (Ru).
10. Nazarov VE. Prichiny bezuspeshnosti eradikacionnoj terapii, ne svyazannye s antibiotikorezistentnostyu *Helicobacter pylori*, i puti ih preodoleniya [Causes of failure of eradication therapy, not associated with *Helicobacter pylori* antibiotic resistance, and ways to overcome them]. *Rossijskij medicinskij zhurnal*. 2018;3:4-12. (Ru).
11. Nikiforova YaV, Tolstova TN, Cherelyuk NI. Osnovnye polozheniya Soglasitelnoj konferencii po diagnostike i lecheniyu *Helicobacter pylori* - Maastricht V (2015) [The main provisions of the consensus conference on diagnosis and treatment *Helicobacter pylori* - Maastricht V (2015)]. *Suchasna gastroenterologija*. 2016; 6(92): 119 – 133. (Ru).

12. Strugatsky D, McNulty RM, Munson K et al. Structure of the proton-gated urea channel from the gastric pathogen *Helicobacter pylori*. *Nature*. 2013; 493: 255-258.
13. Buzas GM, Szeles I. Interpretation of the ¹³C-urea breath test in the choice of second and third-line eradication of *Helicobacter pylori* infection. *J.Gastroenterol.* 2008;43(2):108-14.
14. Dzierzanowska-Fangrat K, Dzierzanowska D. *Helicobacter pylori*: microbiology and interactions with gastrointestinal microflora. *J. Physiol Pharmacol.* 2006; 57 (3): 5-14.
15. Niv Y, Hazazi R. *Helicobacter pylori* recurrence in developed and developing countries: meta-analysis of ¹³C-urea breath test follow-up after eradication. *Helicobacter.* 2008; 13(1): 56-61.

The work is a fragment of research work «Development of information and communication technologies in the system of medical examinations of seamen», the state registration number 0109U008375.

Conflict of interest:

The Author declare no conflict of interest.

CORRESPONDING AUTHOR

Anatoly A. Avramenko

Petro Mohyla Black Sea National University, Mykolaiv, Ukraine

tel: +380976371807

e-mail: aaahelic@gmail.com

Received: 18.03.2019

Accepted: 02.05.2019